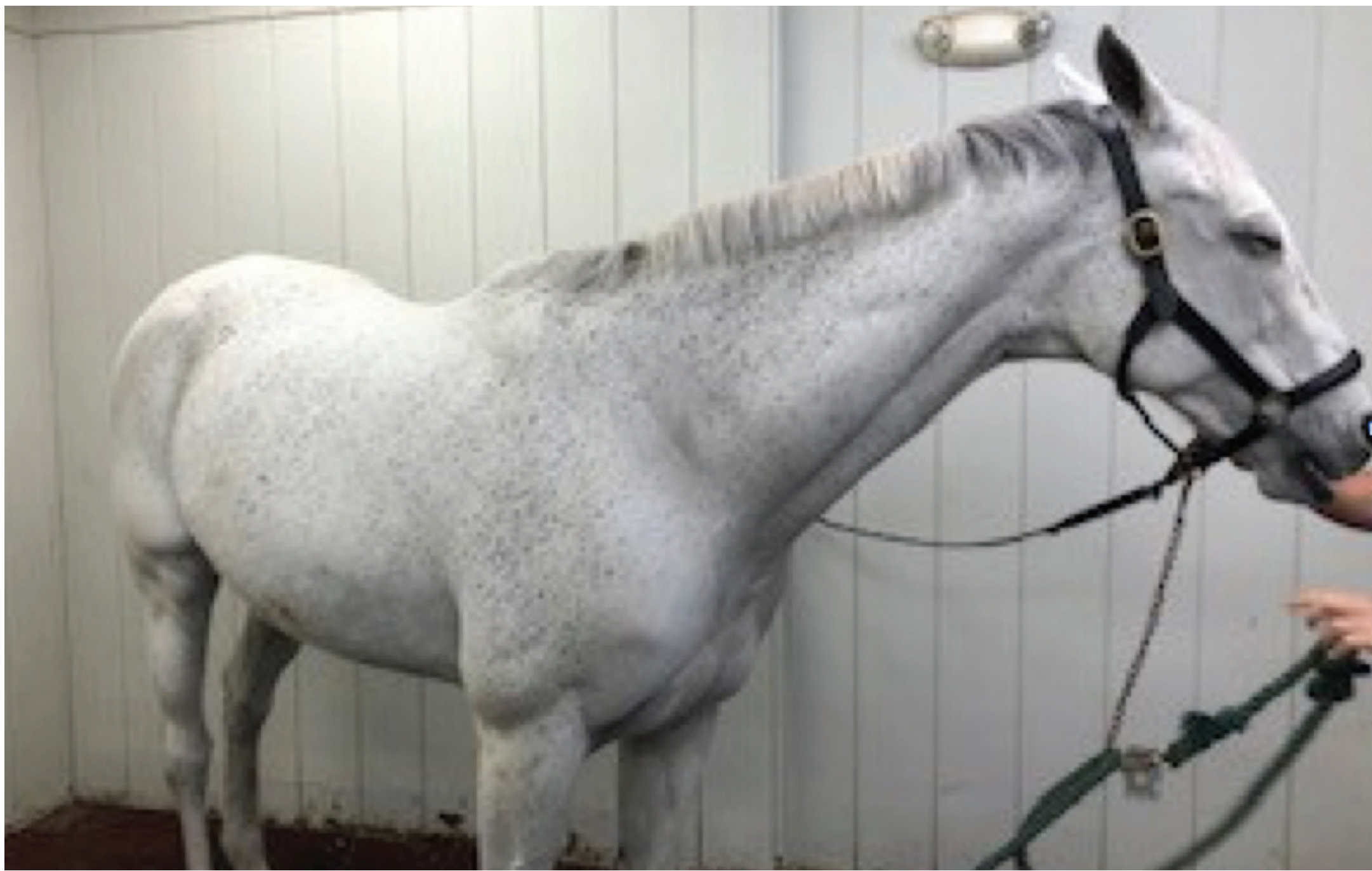
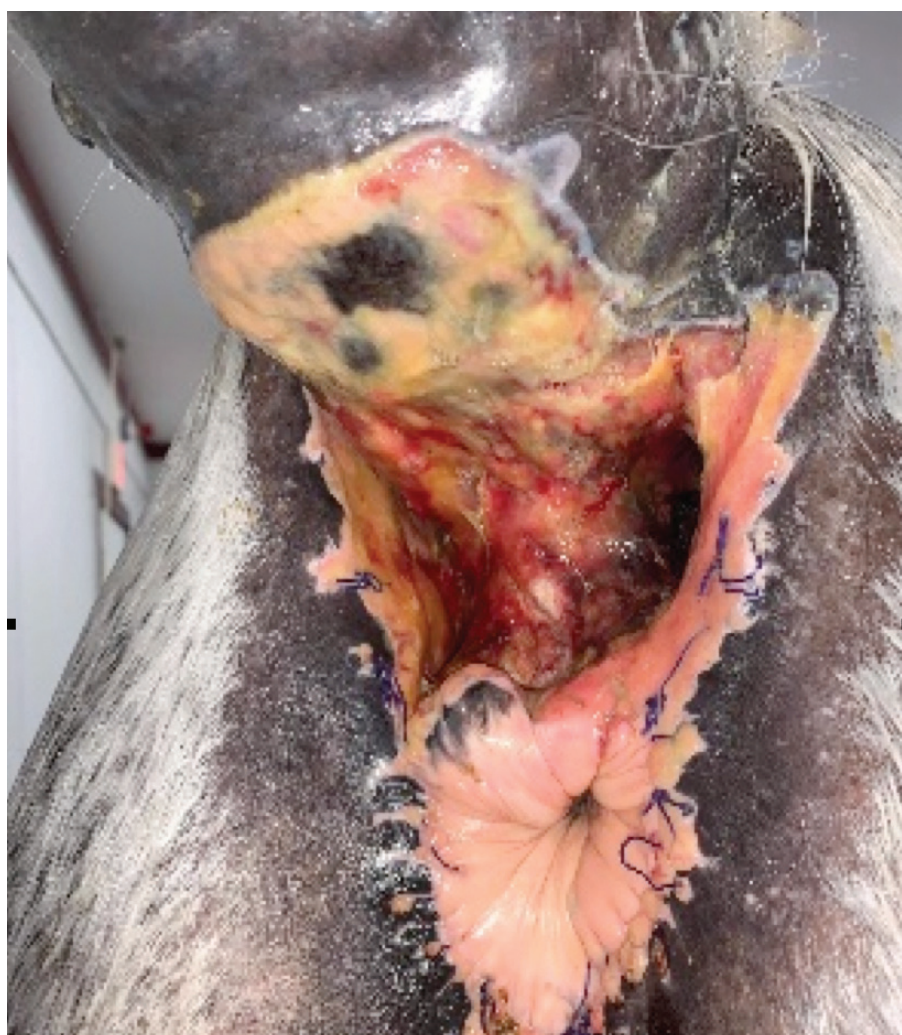
Use of gentian violet and methylene blue antibacterial foam dressings (GV/MB) on an equine wound.

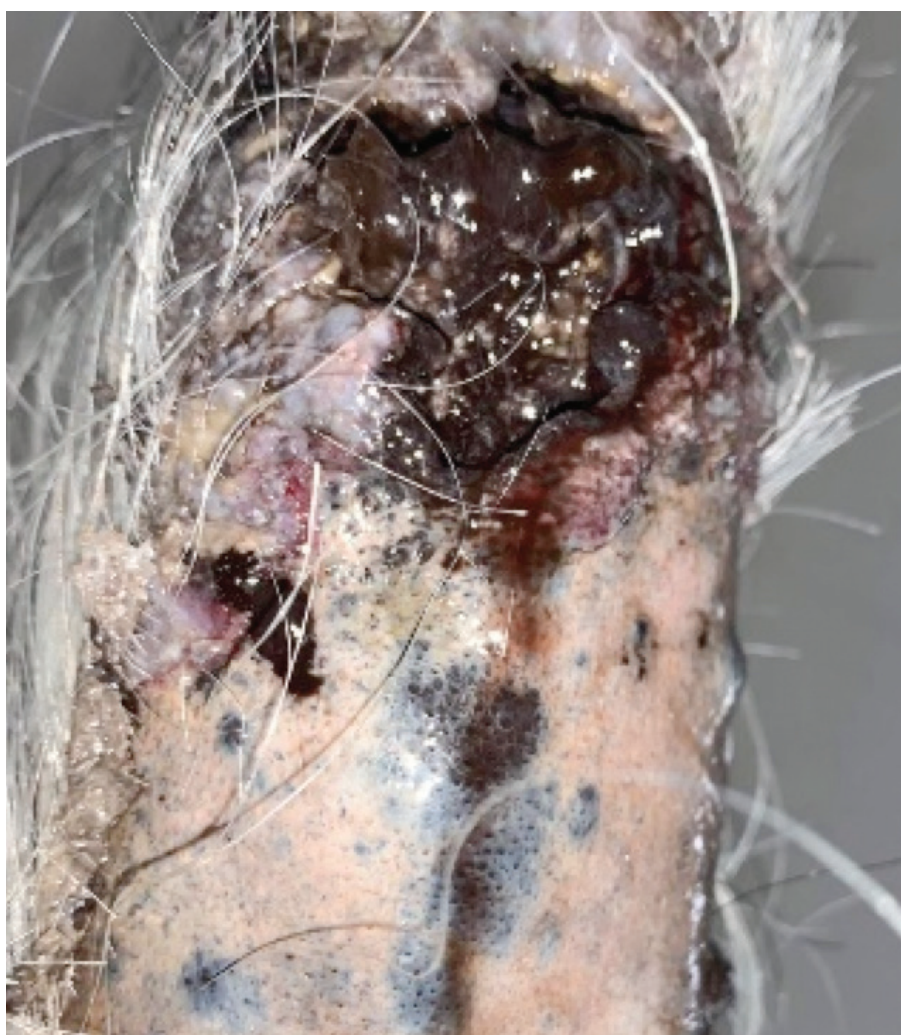

◀ **Name:** Chance
Patient: 17-year-old thoroughbred mare
History: Previous melanoma surgery in 2016
Recurrence of melanoma in January 2020
Melanoma Surgery-January 14, 2020
Tail begins to necrose: January 16
Summation: After 12 days of daily treatment using GV/MB dressings, inflammation decreased, wound is moving quickly toward healing, and pain is noticeably less (mare tolerates tail manipulation and dressing changes without agitation)
Performed at the Myhre Equine Clinic
by Dr. Grant D. Myhre, DVM and Dr. Amr Alsherif, DVM

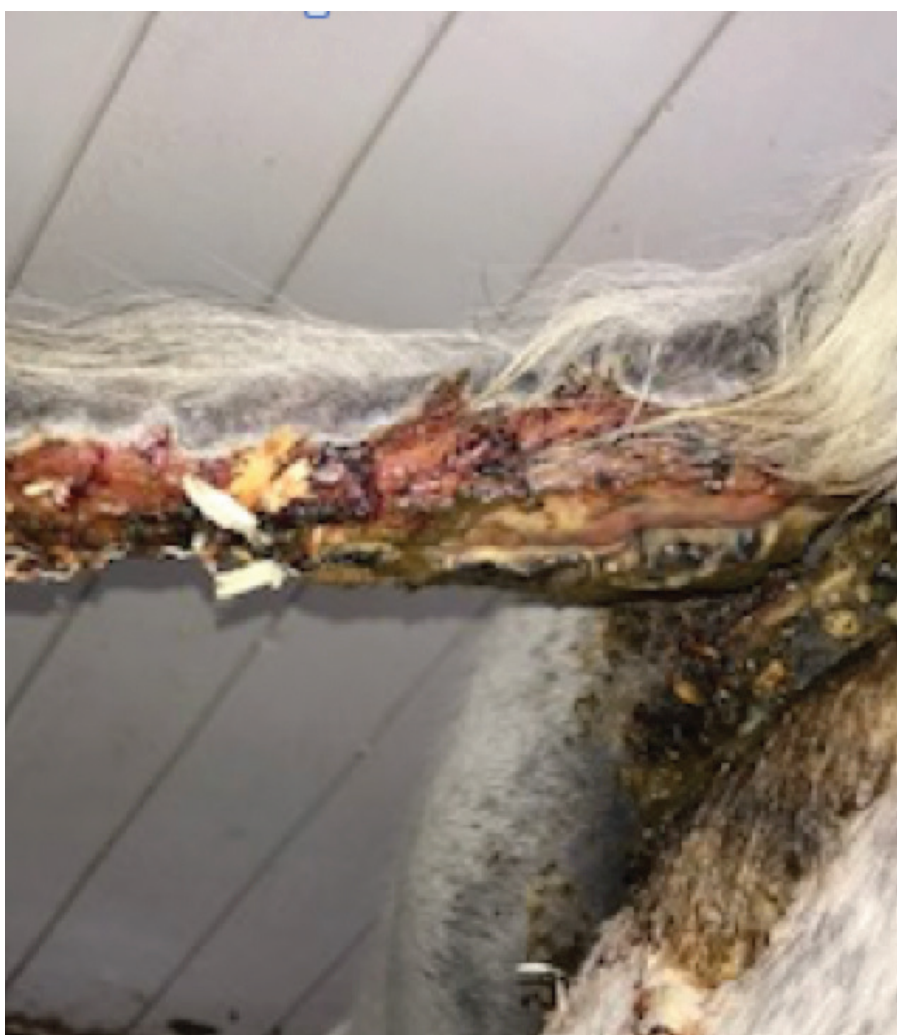Initial Treatment Regimen: Chlorhexidine Spray



1/14/20 Excision of melanoma

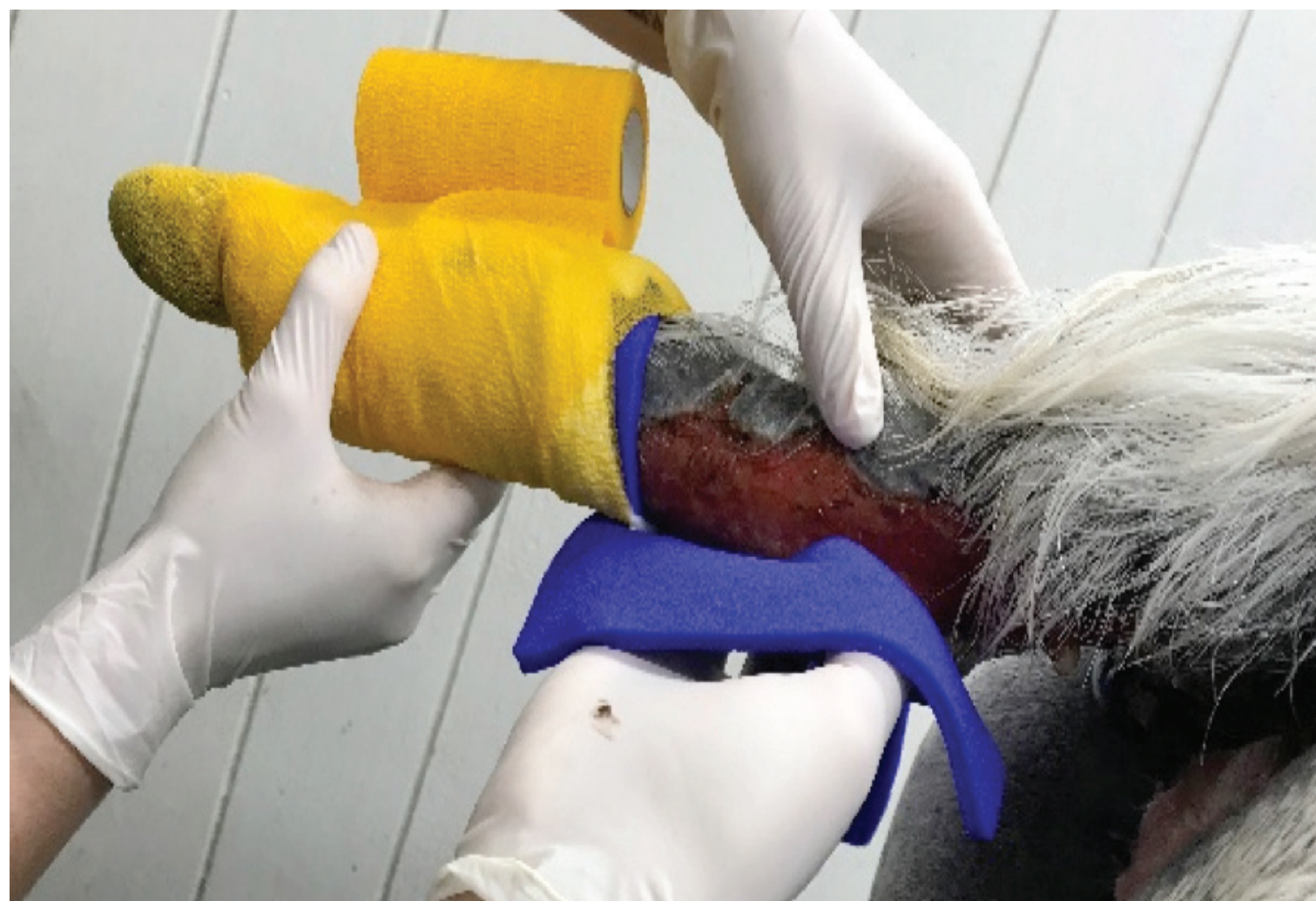

1/16/20 Necrosis at mid-tail




2/21/20 Tail fully necrosed and infected

GV/MB Dressing Applied

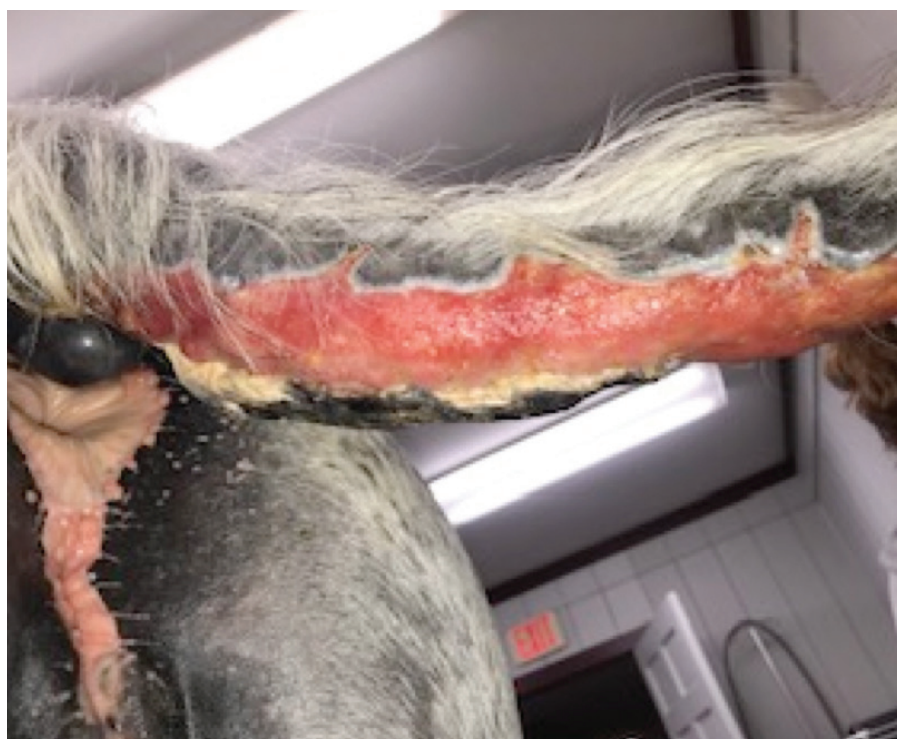
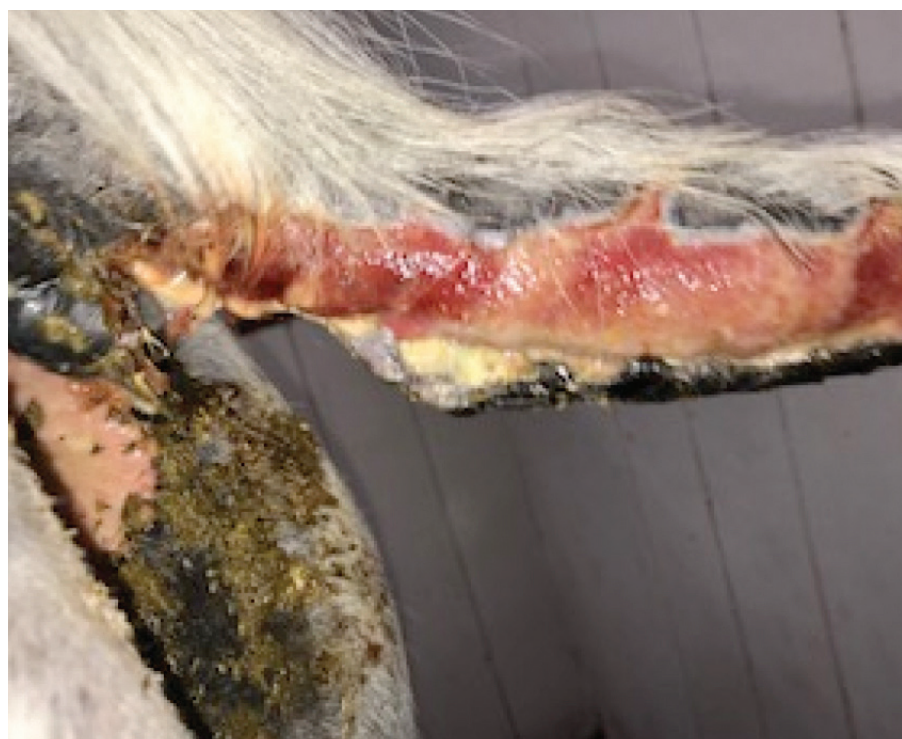
2/21/20

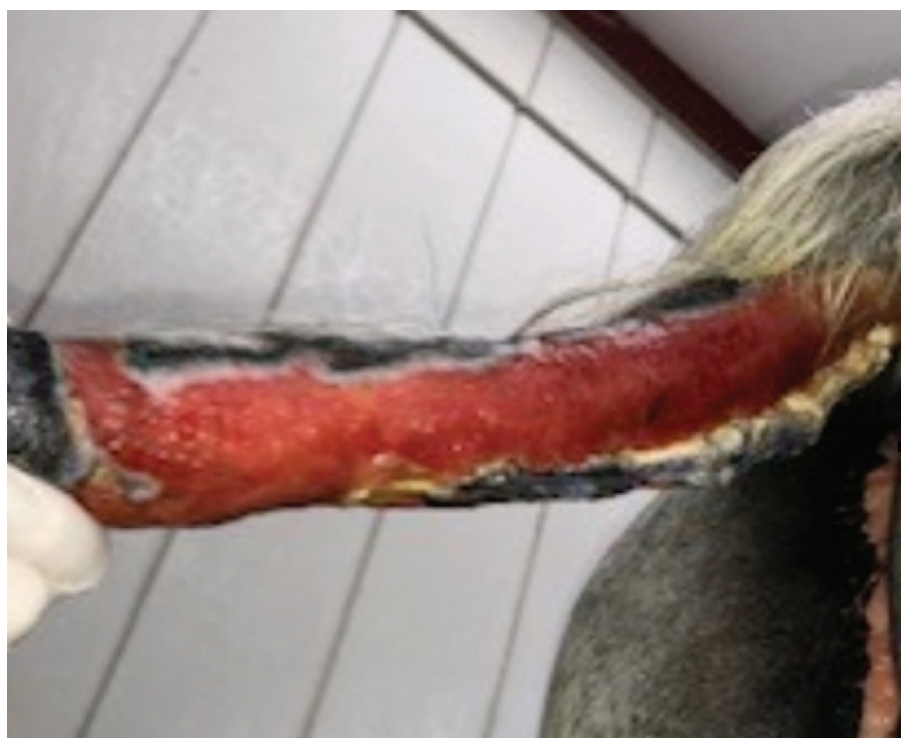First Dressing Change (GV/MB dressing turns white when in contact with bacteria)



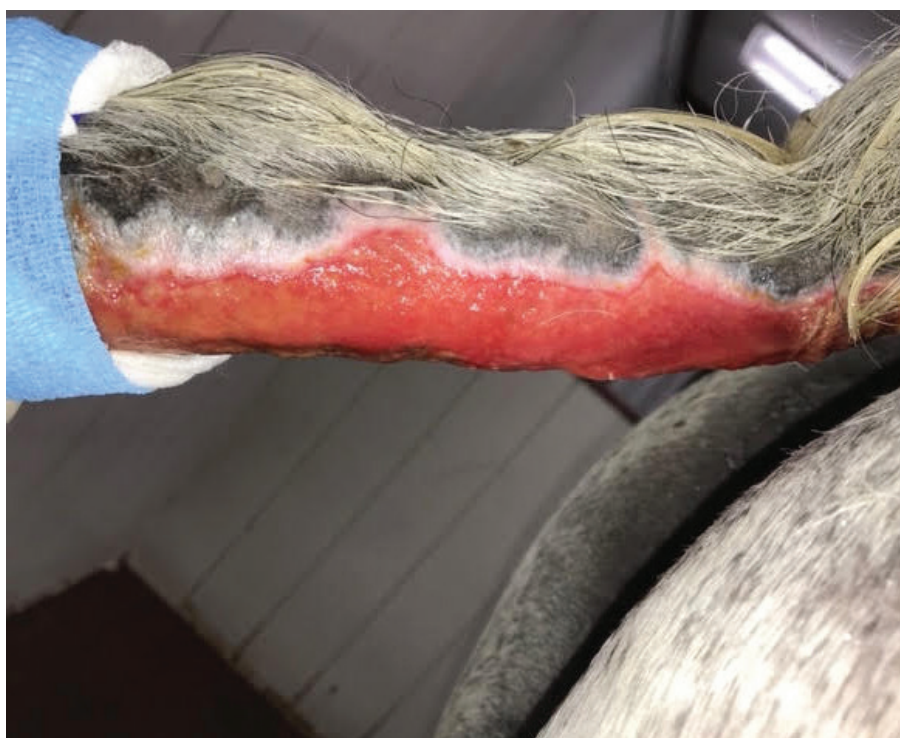2/22/20



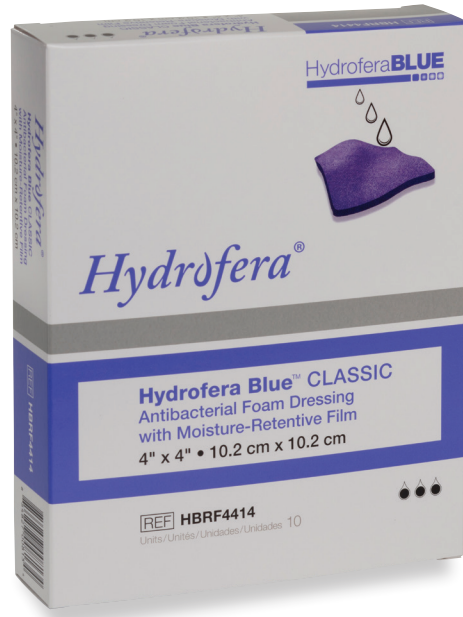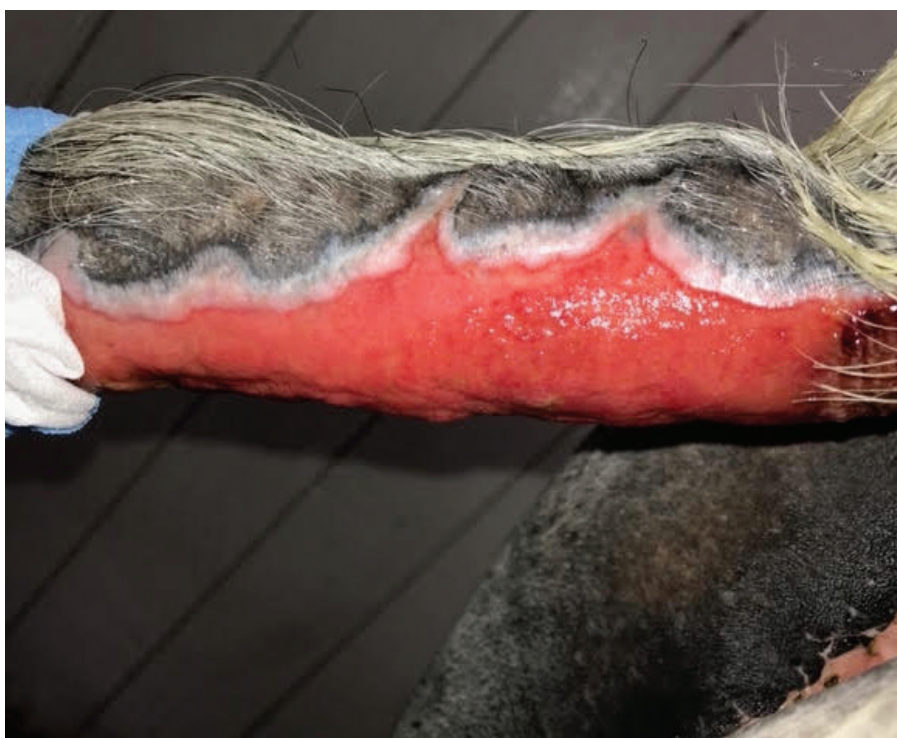Continued Daily Application of Gentian Violet and Methylene Blue Antibacterial Foam Dressing



2/26/20



3/4/20



Find natural balance in *blue*.
Change to blue at hydrofera.com.

055-0320

HydroferaBLUE™