

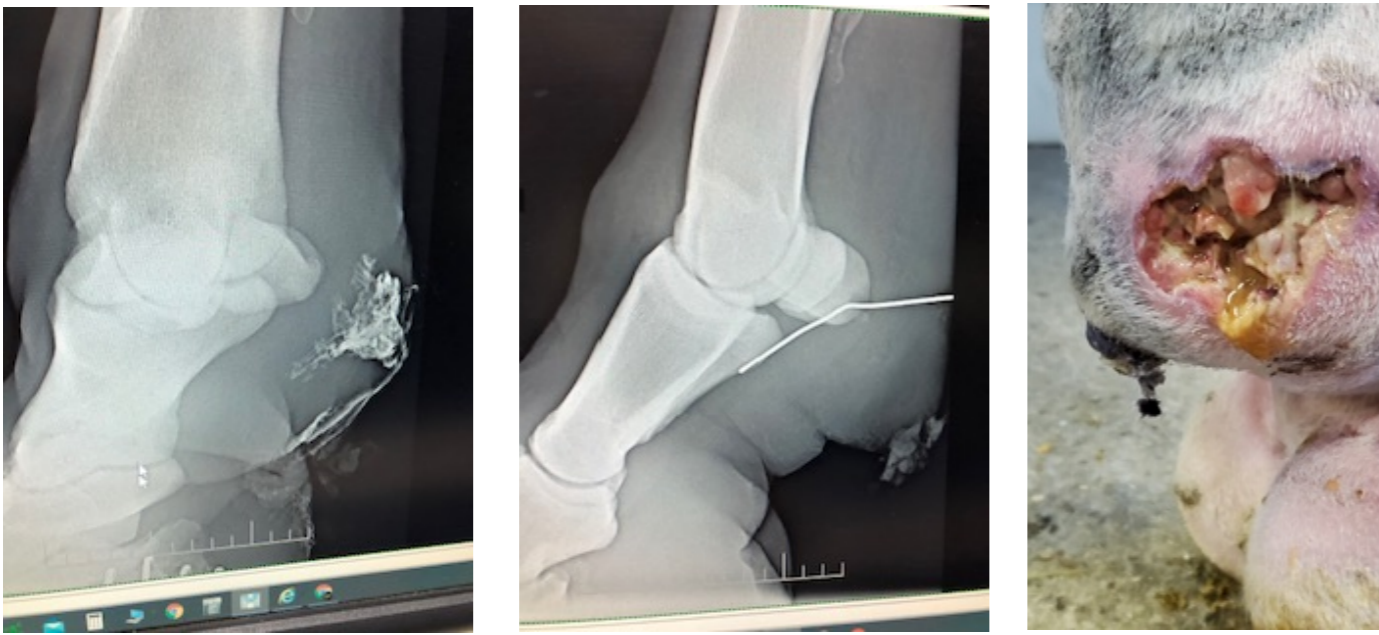
Use of gentian violet and methylene blue antibacterial foam dressings (GV/MB) on an equine wound.



Name: Fred
 Patient: 20-year-old Belgium gelding
 Weight: 2,200 lbs.
 History: Injury date March 15, 2020
 Cellulitis combined with Oedema
 Wound of unknown etiology
 Antibiotics: Oxytetracycline,
 Minocycline and Bute
 March 20, 2020 began Hydrofera **VetBlue**

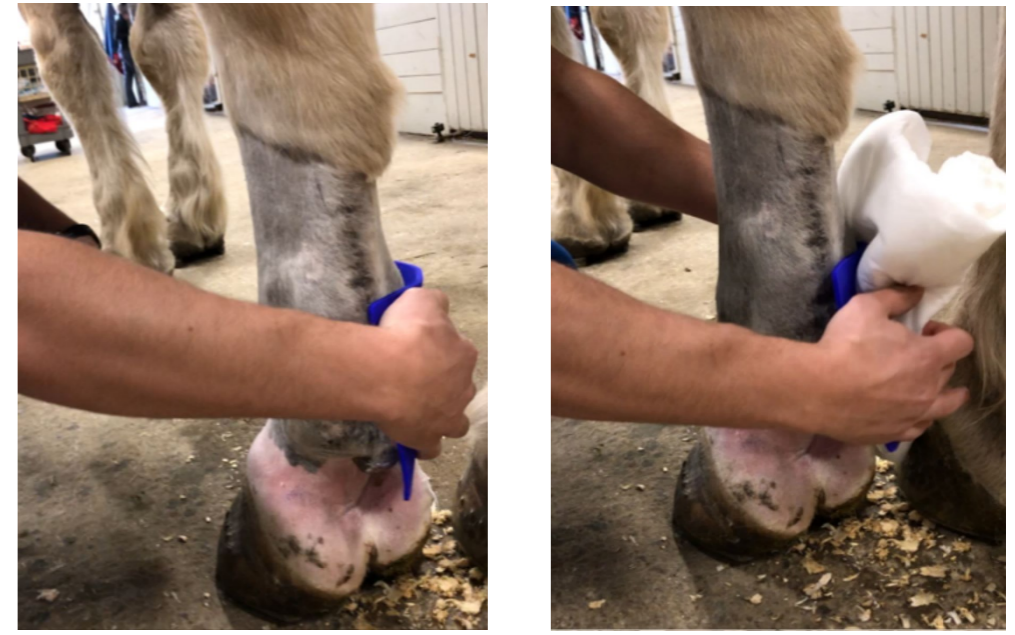Performed at the Myhre Equine Clinic
 by Dr. Grant D. Myhre, DVM and Dr. Amr Alsherif, DVM

Cat Scan Showing Depth and Extent Of Fetlock Injury



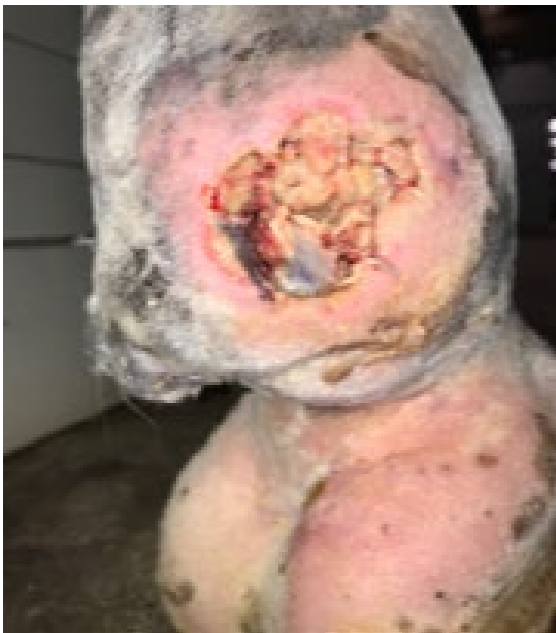3/15/2020 Cellulitis combined with Edema; Cat Scan confirmed joint was not comprised

GV/MB Dressing Applied

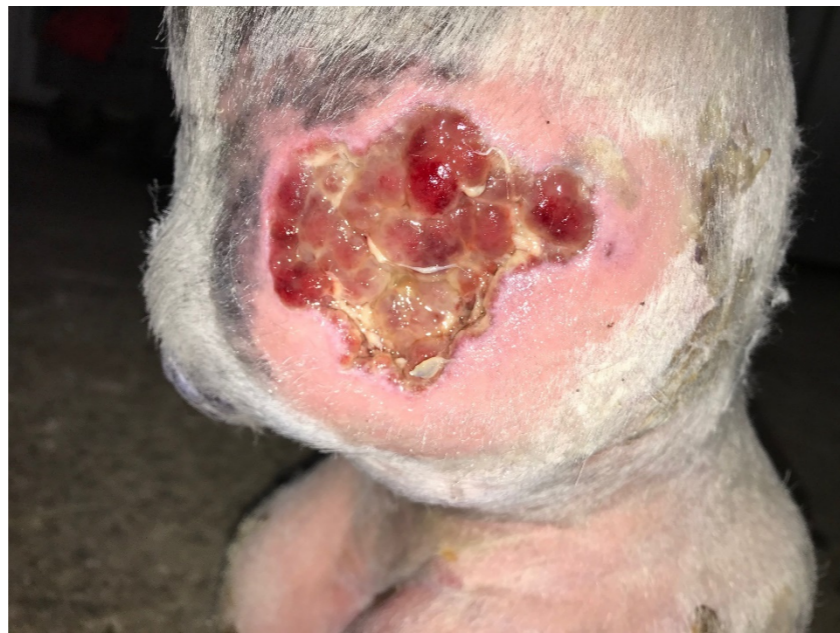

3/20/2020

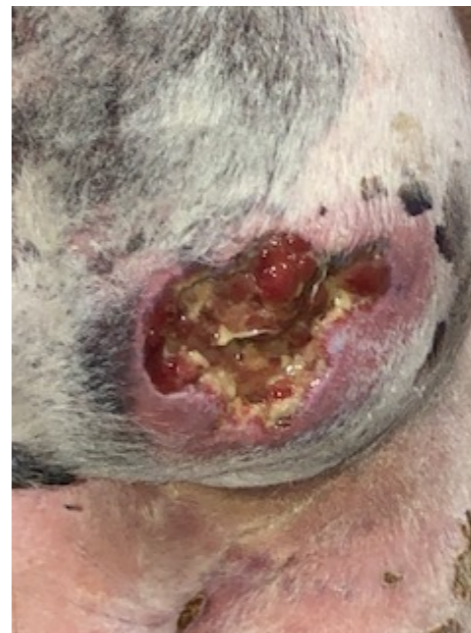Gentian Violet and Methylene Blue Antibacterial Foam Dressing Provides Debridement Essential to The Continued Wound Healing Process



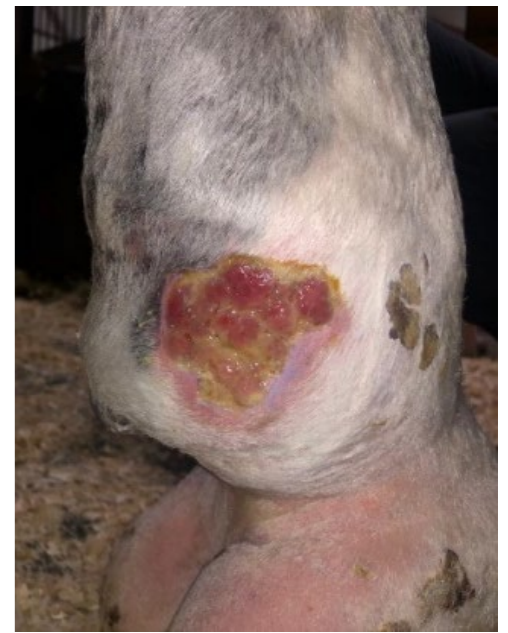3/29/2020



4/2/2020

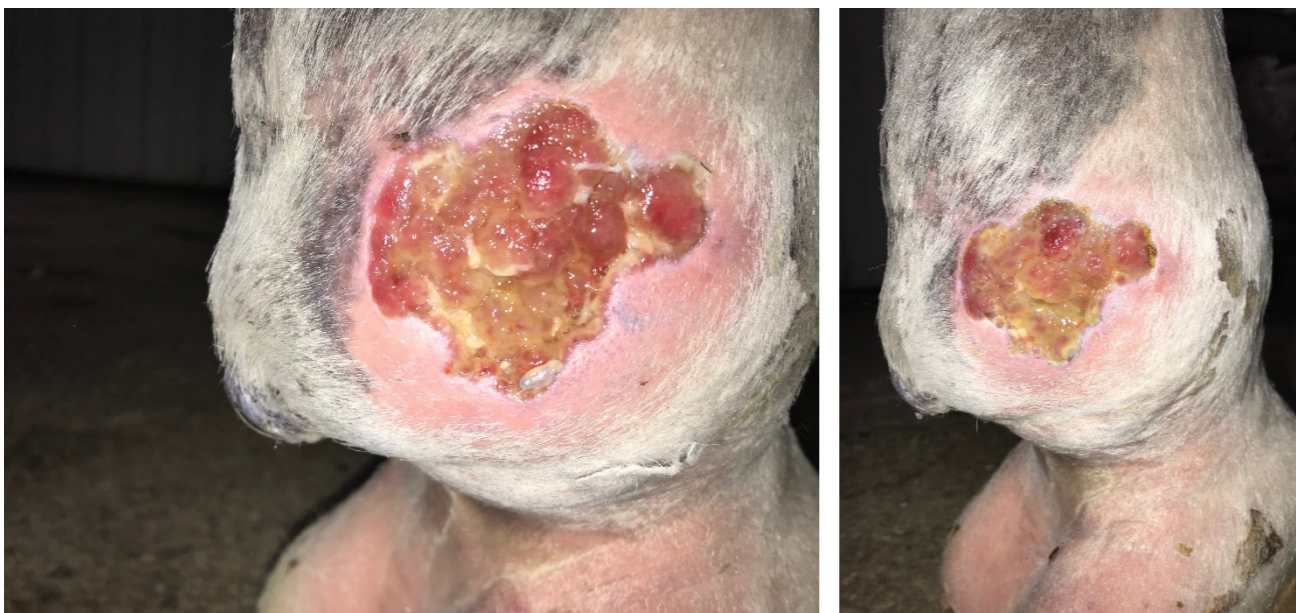

4/6/2020



4/14/2020

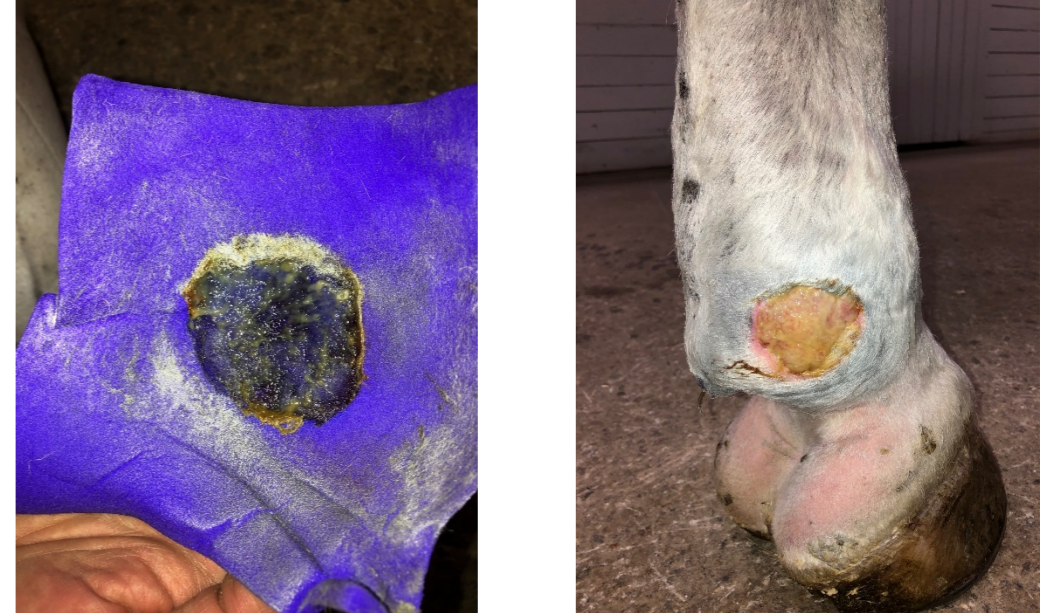Transition From Hydrofera to Silver Based Spray for Two Days



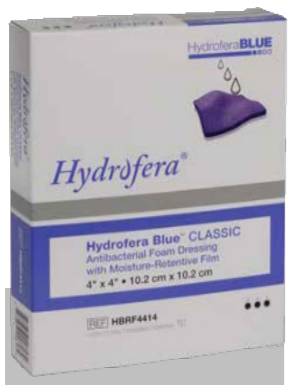4/4/20

4/6/20

Transitioned Back to Hydrofera Due to Wound Deterioration



4/24/20



Find natural balance in **blue**.
 Change to blue at hydrofera.com.

055-0320

HydroferaBLUE™